

BASIC MEDICAL SCIENCE

FSC MEDICAL TECHNOLOGIES I

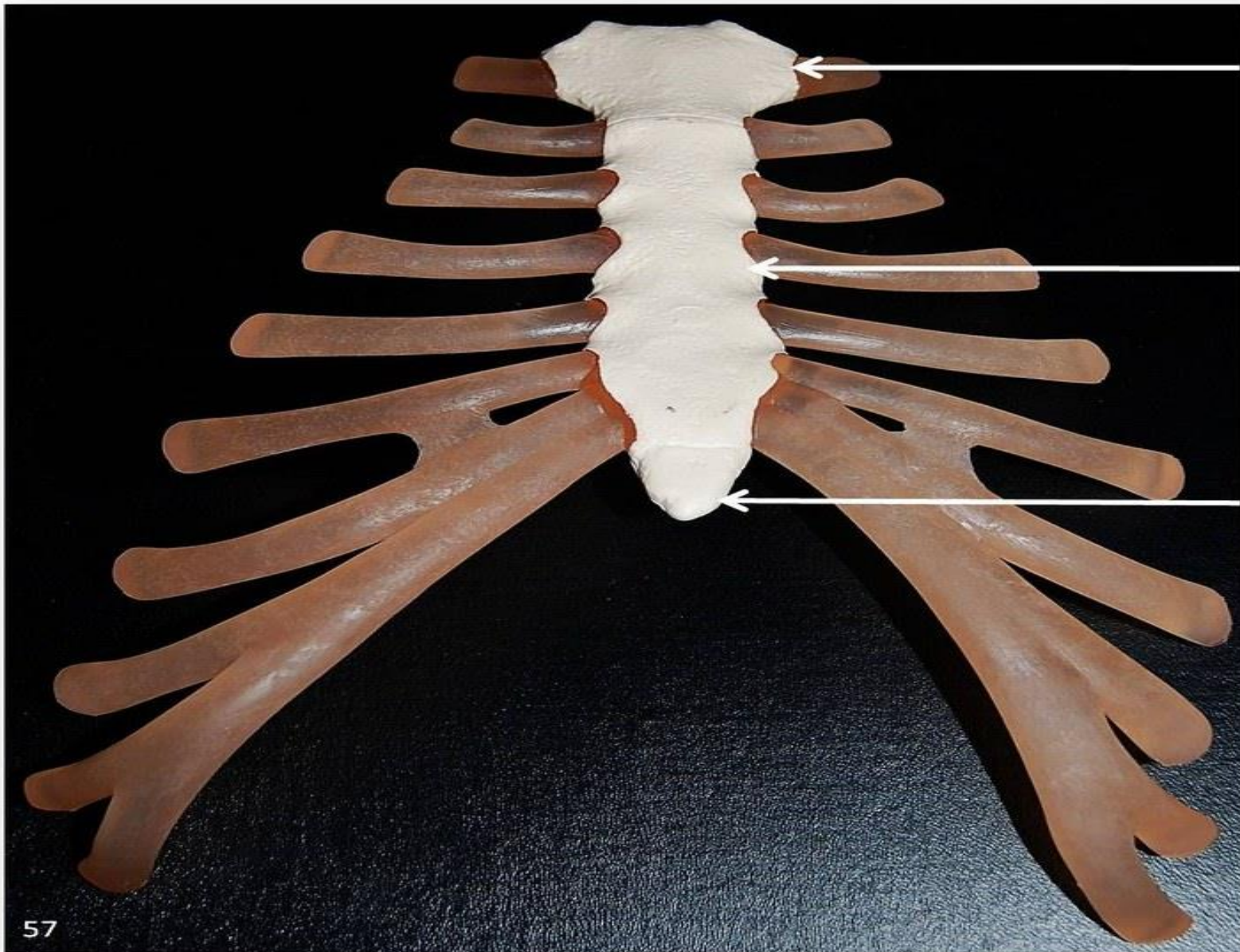
DR DANISH

BONES OF THORAX

- Sternum
- Ribs

Sternum

- The breastbone located in center of chest
- Consists of the manubrium,body,&xiphoid process



Manubrium

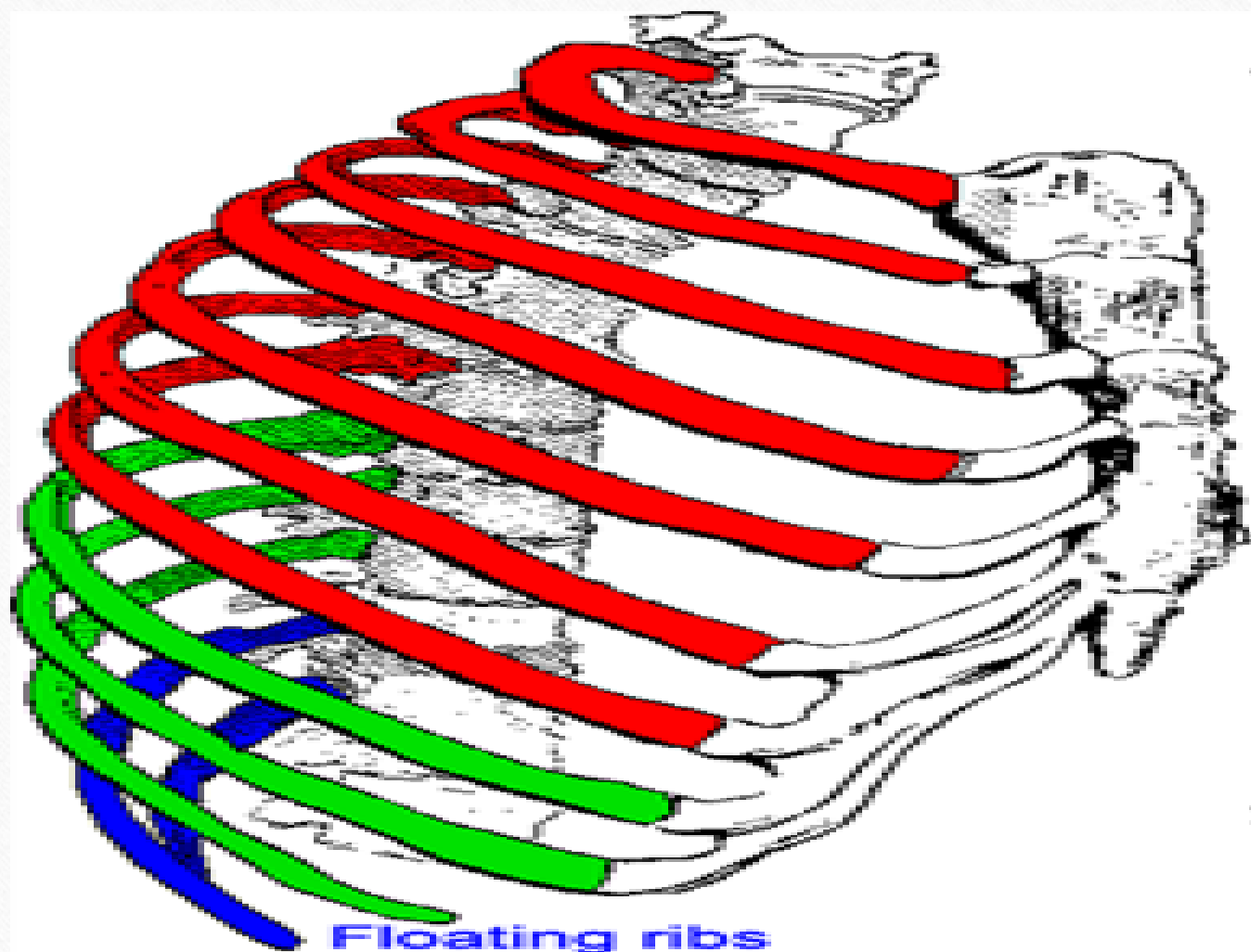
Body of sternum

Xiphoid process

Sternum.
Anterior view

Ribs

- There 12 pairs of ribs
- First seven are called true ribs because they attach directly to sternum
- The next 3 pairs are false ribs & last 2 pairs are floating ribs



Floating ribs
(11,12)

True ribs
(1-7)

False ribs
(8-12)

Bones of the Pelvis

- Composed of three fused bones; the ilium, ischium, & pubis
- Articulates with sacrum at sacroiliac joint & with femur at hip joint

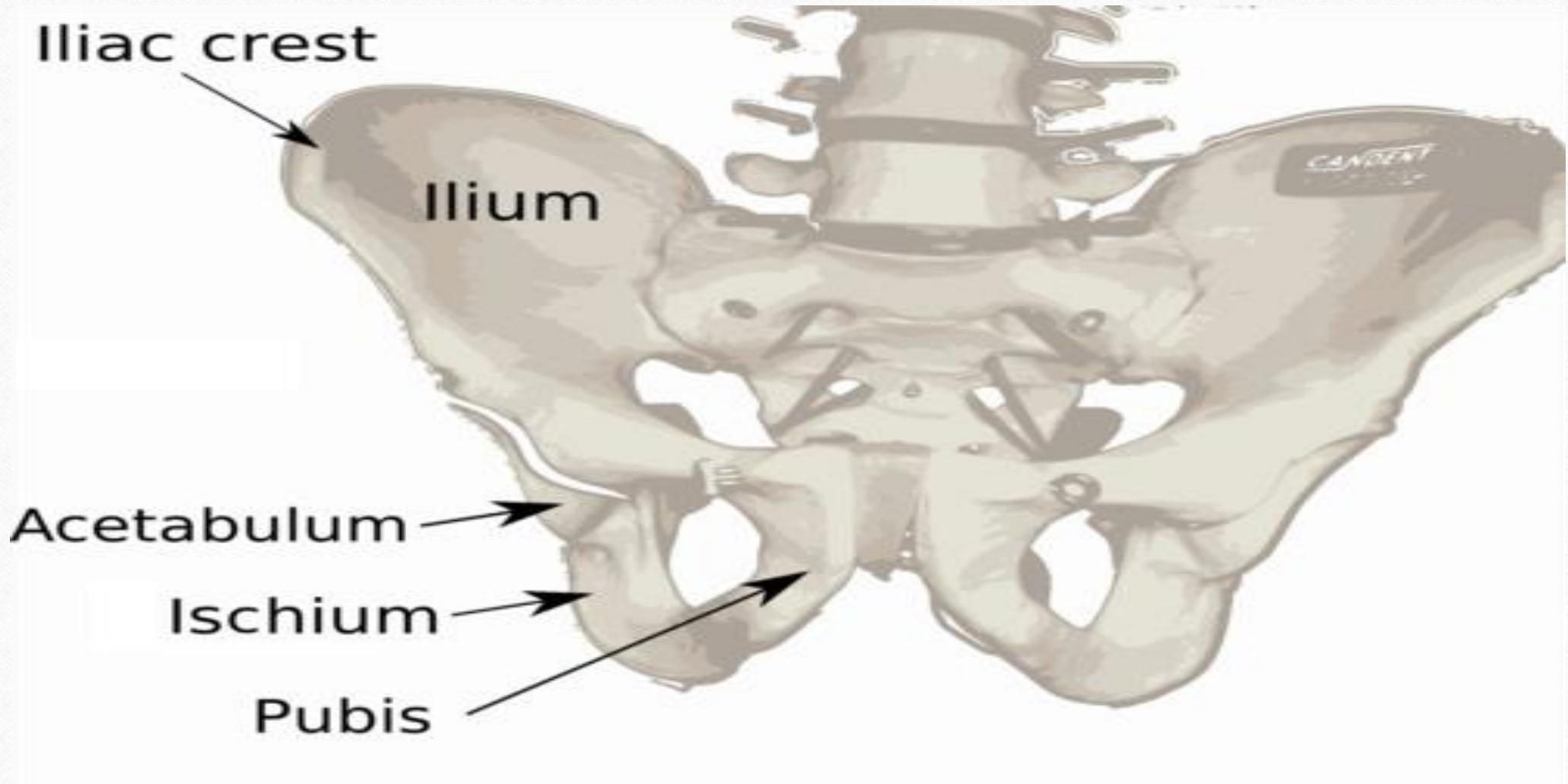
Iliac crest

Ilium

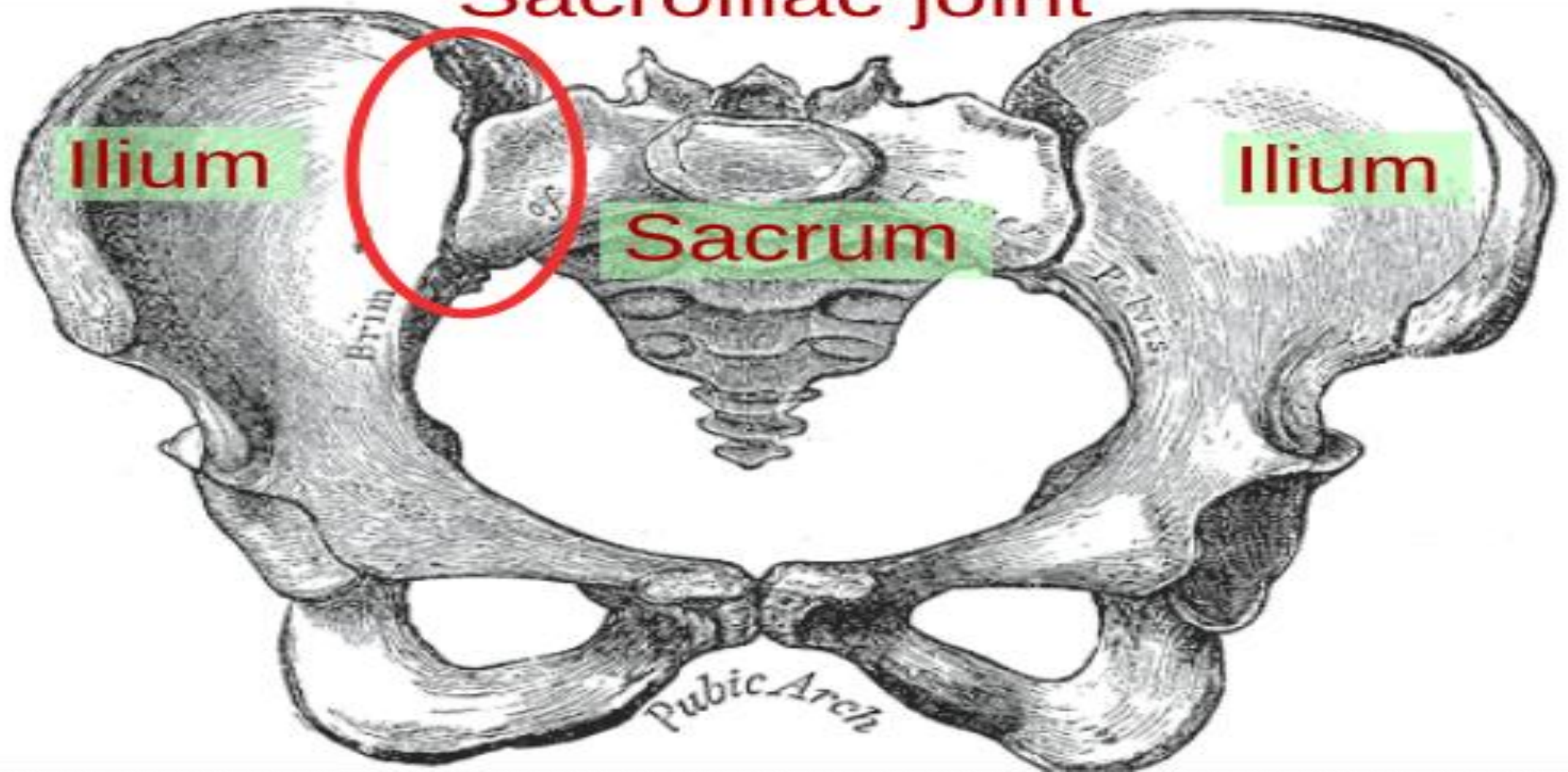
Acetabulum

Ischium

Pubis



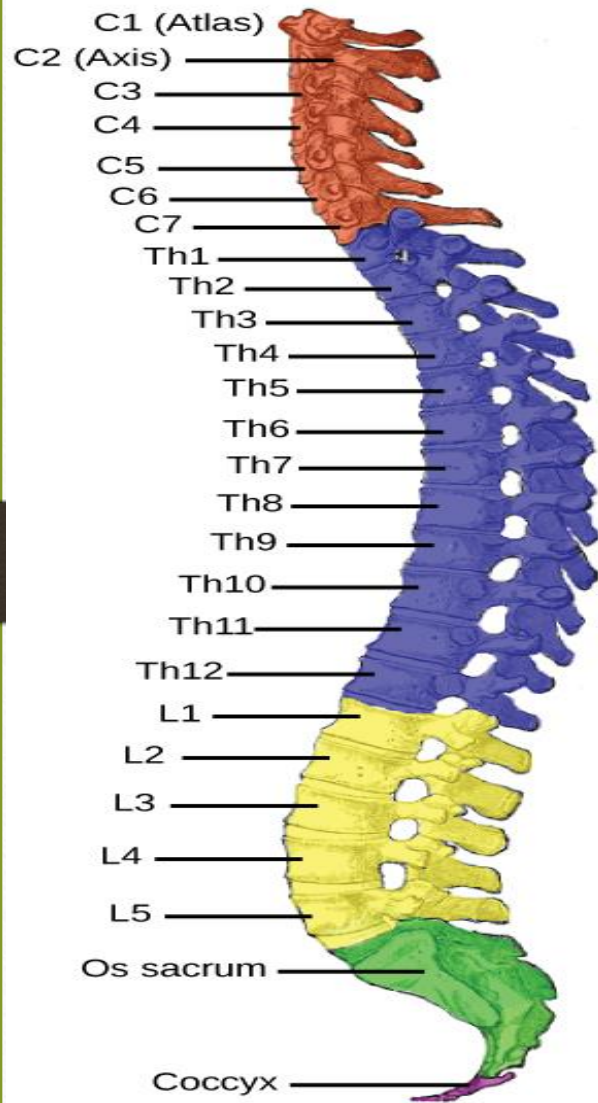
Sacroiliac joint



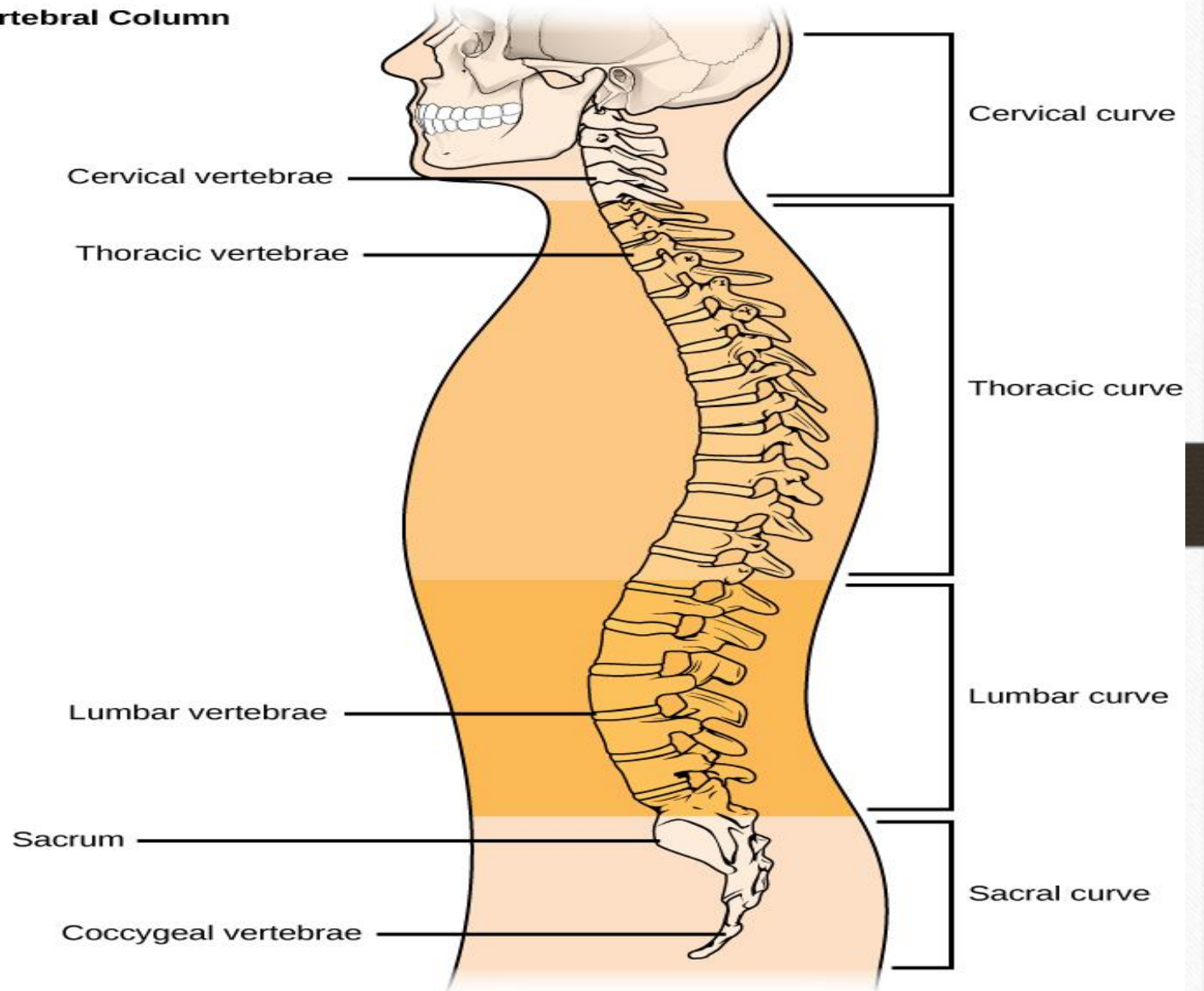
Vertebral column

CERVICAL VERTEBRAE

- 7 vertebrae in neck region
- C1 to C7



Vertebral Column



THORACIC VERTEBRAE

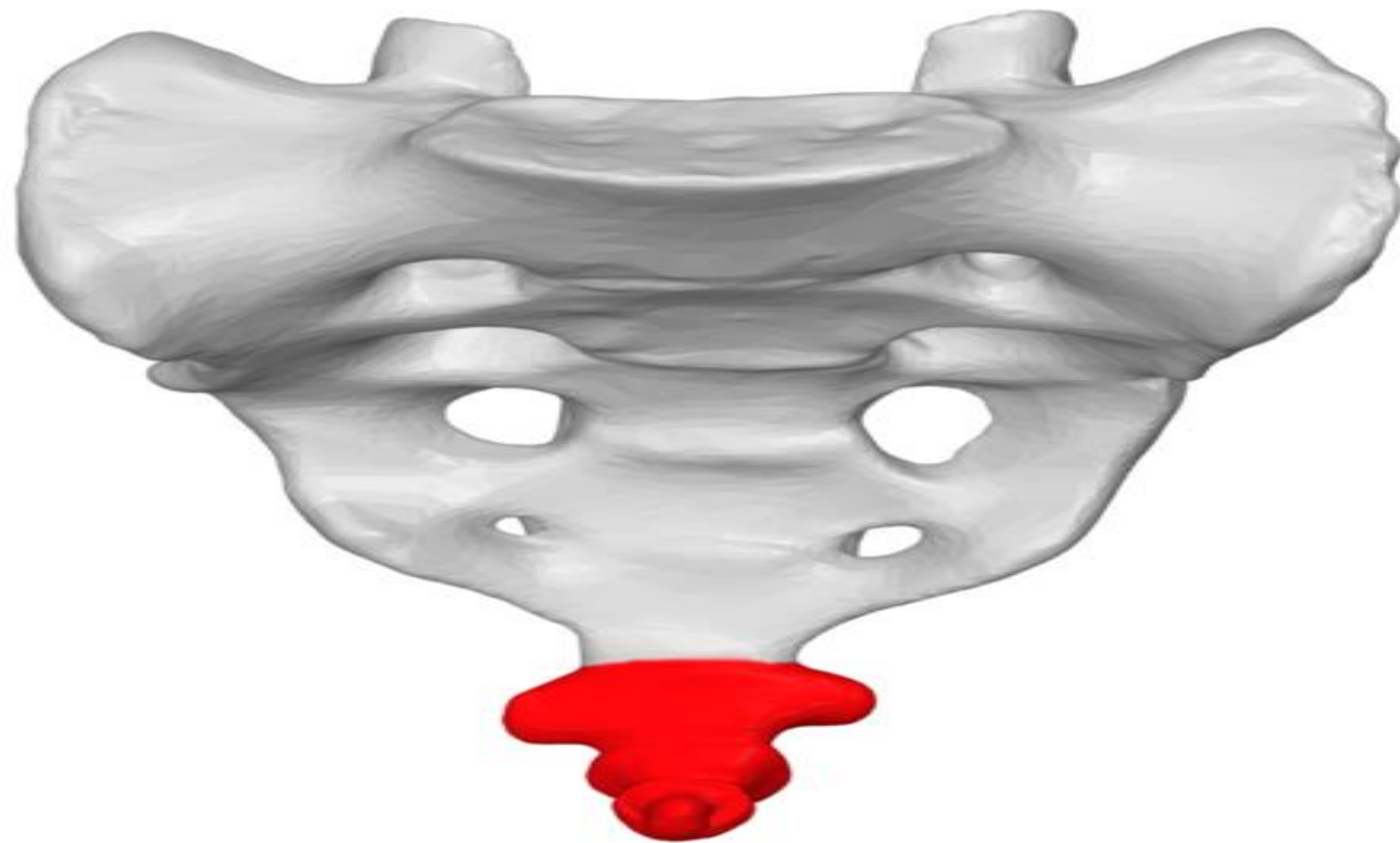
- 12 vertebrae in upper back
- T1 to T12

LUMBAR VERTEBRAE

- 5 vertebrae in lower back
- L1 to L5

Sacrum & Coccyx

- Triangular bone formed by fusion of 5 sacral vertebrae
- Coccyx bone / tailbone formed by fusion of 4 coccygeal vertebrae





THANK
YOU